

Cutaneous Manifestations of Disseminated Toxoplasmosis in an Immunosuppressed Dog

A 3.5-year-old, castrated male, giant schnauzer was presented with alopecic pustular dermatitis. Immune-mediated hemolytic anemia had been diagnosed 45 days previously. At the time of presentation, the dog was receiving prednisone, azathioprine, and cyclosporine. Cutaneous protozoosis was diagnosed, and postmortem examination revealed protozoa within cutaneous, cardiac, pancreatic, and pulmonary tissues. The protozoa divided by endodyogeny, had the morphology of *Toxoplasma gondii* (*T. gondii*) tachyzoites, and stained positively with *T. gondii* polyclonal antibodies but not with antibodies to *Neospora caninum* or *Sarcocystis neurona*. Immunosuppression may have predisposed this dog to disseminated toxoplasmosis. *J Am Anim Hosp Assoc* 2005;41:198-202.

Jinelle A. Webb, DVM, MSc

Sonya L. Keller, DVM

Erin P. Southorn, DVM,
Diplomate ACVP

Julie Armstrong, DVM, MVSc,
Diplomate ACVIM

Dana G. Allen, DVM, MSc,
Diplomate ACVIM

Andrew S. Peregrine, BVMS,
PhD, DVM

J.P. Dubey, MVSc, PhD

CR

From the Departments of Clinical Studies (Webb, Armstrong, Allen) and Pathobiology (Keller, Southorn, Peregrine), Ontario Veterinary College, University of Guelph, Guelph, Ontario, Canada N1G 2W1 and the Animal Parasitic Diseases Laboratory (Dubey), Animal and Natural Resources Institute, Agricultural Research Service, United States Department of Agriculture, BARC-East, Building 1001, Beltsville, Maryland 20705-2350.

Dr. Armstrong's current address is Medi-Cal, 67 Watson Road South, Guelph, Ontario, Canada N1H 6H8.

Introduction

Toxoplasma gondii (*T. gondii*), an obligate intracellular parasite, is found worldwide in a broad range of warm-blooded animals.¹⁻⁴ Seroprevalence in humans and animals can reach almost 100% in endemic areas where raw or undercooked meat is widely consumed.^{2,3} Although the cat is the definitive host for *T. gondii*, virtually any mammal, including a human, can act as an intermediate host. The two components of the life cycle of *Toxoplasma* include an enteroepithelial cycle that occurs only in the cat, and an extraintestinal or tissue cycle that occurs in both cats and other species. Infection of intermediate hosts begins via consumption of tissue cysts in muscle, ingestion of sporulated oocysts in food or water contaminated by feces, or transplacental transmission in some species. The ingested organisms penetrate the enterocytes, and parasitemia ensues. In the majority of cases, immunity develops and resolves much of the infection. However, bradyzoites often remain in tissue cysts that may persist in any organ, including the skin, for the life of the host. A latently infected animal may experience intermittent reactivation of tissue cysts, usually without producing any clinical signs.

Toxoplasma gondii causes tissue damage via intracellular growth, resulting in cell necrosis; it does not produce a toxin.^{1,2} The localization of the tissue damage dictates the clinical signs and also the severity of the infection. If the organism is acquired via ingestion of oocysts or tissue cysts, gastrointestinal signs may predominate initially from local destruction by tachyzoites, followed by systemic spread.² In the dog, the respiratory, intestinal, and neuromuscular systems are most commonly involved. Cutaneous involvement has not been previously reported.^{2,4-6}

In an immune-competent individual, cell-mediated immunity controls proliferation of the organism while humoral immunity plays a lesser role.^{1,7-9} Immunosuppressive drugs, including glucocorticoids and other cytotoxic drugs, depress the mononuclear and macrophage immune response and permit the development of overt clinical toxoplasmosis.^{2,6,10,11} Immunosuppression has been linked to a higher incidence of clinical toxoplasmosis in humans, dogs, and cats.^{2,9,10,12-14} There is no evidence that immunosuppression causes the rupture of tissue cysts, and

clinical toxoplasmosis probably occurs in most cases from recrudescence of a latent infection.^{1,7,9,10} In addition, clinical toxoplasmosis may occur in immunosuppressed humans and animals exposed to *T. gondii* via organ transplantation or blood transfusion.^{2,7-9,13,15}

The purpose of this paper is to describe a case of disseminated toxoplasmosis with cutaneous involvement in an immunosuppressed dog.

Case Report

A 3.5-year-old, castrated male, giant schnauzer was presented to the Veterinary Teaching Hospital (VTH), Ontario Veterinary College, with a complaint of alopecia, multiple ulcerated skin nodules, anorexia, and lethargy. The dog had been diagnosed with idiopathic immune-mediated hemolytic anemia (IMHA) 1.5 months previously (day 0) and had required five packed red blood cell transfusions. The dog was discharged from the VTH on day 10, with immunosuppressive therapy consisting of prednisone^a (2 mg/kg per os [PO] *q* 24 hours), azathioprine^b (2 mg/kg PO *q* 24 hours), and cyclosporine^c (5 mg/kg PO *q* 12 hours). The referring veterinarian monitored clinical signs and laboratory values thereafter. On follow-up examinations, the dog had gained weight, and the packed cell volume ranged from 25% to 30%.

Thirty days after discharge, the owners noted alopecia on the dog. Small dermal ulcerations were first observed on day 38. A 1-day history of anorexia and lethargy prompted a visit to the VTH on day 45. On physical examination, the dog was markedly cachectic and lethargic. The mucous membranes were pale and icteric. Cutaneous lesions included 12 well-circumscribed, raised, alopecic nodules ranging from 0.5 to 3 cm in diameter with ulcerated, depressed centers [Figure 1]. Purulent-appearing material was expressed from some lesions. The underlying soft tissue was swollen and warm on palpation. The lesions were located over the right and left scapular regions, proximal left forelimb, tip of the left pinna, proximal left and right hind limbs, medial right metatarsal region, and left jugular groove.

Initial diagnostic tests included a complete blood cell count (CBC), serum biochemical profile, urinalysis, and

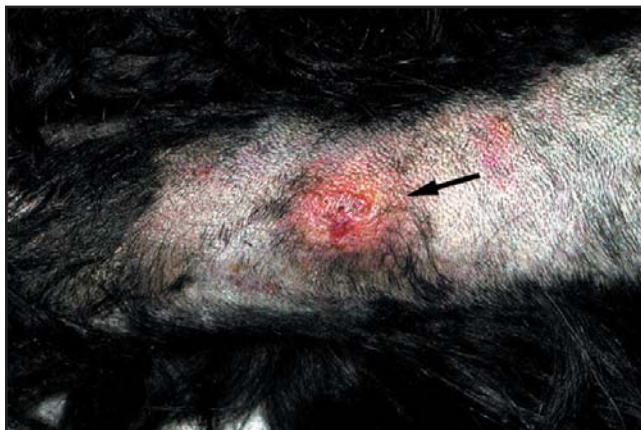

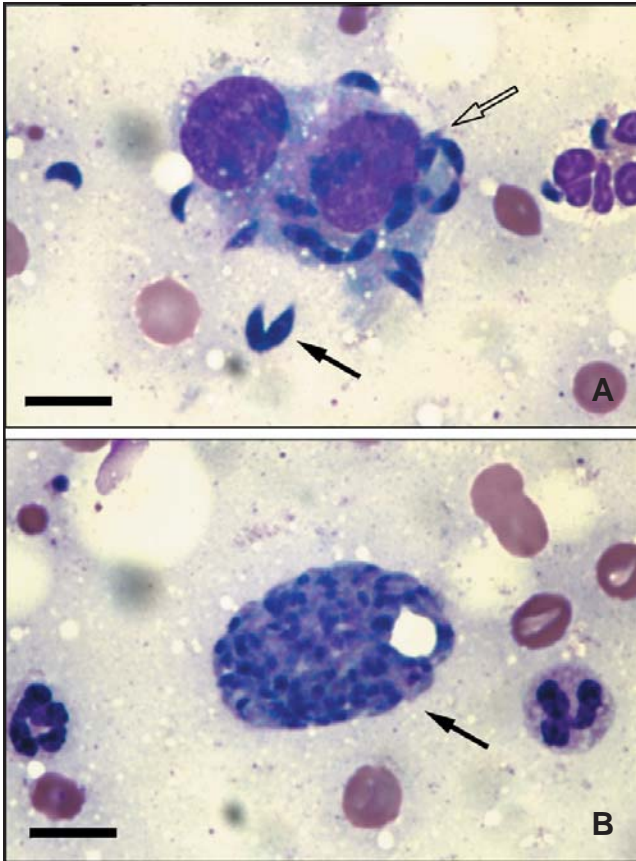
Figure 1—Alopecic pustular dermatitis (arrow) on the left forelimb of a 3.5-year-old giant schnauzer with disseminated toxoplasmosis.

urine culture. Results of the CBC revealed anemia (hematocrit 23%; reference range 39% to 56%) and lymphopenia (0.13×10^3 cells/ μ L; reference range 0.8 to 5.1×10^3 cells/ μ L). Evaluation of the blood smear was consistent with a poorly regenerative anemia. Biochemical profile showed panhypoproteinemia (total protein 45 g/L; reference range 55 to 74 g/L; albumin 26 g/L; reference range 29 to 43 g/L; globulin 19 g/L; reference range 21 to 42 g/L), hypocalcemia (2.20 mmol/L; reference range 2.30 to 2.80 mmol/L), and elevations in total bilirubin (18 μ mol/L; reference range 0 to 4 μ mol/L), alkaline phosphatase (2161 U/L; reference range 22 to 142 U/L), alanine transaminase (753 U/L; reference range 19 to 107 U/L), γ -glutamyltransferase (202 U/L; reference range 0 to 7 U/L), and lipase (1370 U/L; reference range 60 to 848 U/L). Urinalysis collected via cystocentesis had a specific gravity of 1.029. Pyuria and bacteria were also noted, and an aerobic culture grew *Escherichia coli*.

Fine-needle aspirates of cutaneous lesions from the right flank, jugular groove, and scapular region were performed. In all aspirates, a large number of tachyzoites (approximately $2 \times 5 \mu$ m) with light basophilic cytoplasm and a central, small nucleus were present, mainly as individual extracellular organisms. Low numbers of the organisms were also present within macrophages [Figure 2A], and one cluster of approximately 50 tachyzoites was also seen [Figure 2B]. Serum was submitted for *T. gondii* and *Neospora caninum* (*N. caninum*) antibody titers. Antibodies to *T. gondii* were found in the serum at a titer of 1:64 by indirect hemagglutination.^d Antibodies to *N. caninum* were not found (enzyme-linked immunosorbent assay;^e 7.6% inhibition, negative = <30% inhibition). The dog was diagnosed with cutaneous protozoosis, and recommendations included supportive care and clindamycin therapy. The owners elected euthanasia, and a postmortem examination was performed.

On necropsy, gross lesions were restricted to the lungs, stomach, and adrenal glands. Tan, irregular round nodules ($n=10$, 2 to 5 mm in diameter) were randomly scattered throughout the lungs. Regionally extensive, firm, mottled red and white areas were noted in approximately 50% of the pulmonary parenchyma. Multiple, pinpoint, hemorrhagic ulcerations in the gastric fundus were found, and intestinal contents were melenic. Bilateral adrenocortical atrophy and a low cortical to medullary ratio of 0.5:1 (consistent with recent high-dose corticosteroid therapy) were also found. The liver was mildly friable and golden tan, consistent with steroid hepatopathy.

Histological examination revealed widespread necrotizing lesions. Skin lesions consisted of extensive areas of deep and superficial dermal necrosis with marked, pyogranulomatous inflammation. Within lesions, numerous protozoal tachyzoites were observed in macrophages, fibroblasts, and endothelial cells, as well as free in the tissues [Figure 3]. The epithelium over the lesions was ulcerated and covered by a thick crust containing numerous bacterial colonies. The adjacent epithelium was acanthotic with compact orthokeratotic hyperkeratosis.



Figures 2A, 2B—*Toxoplasma gondii* tachyzoites, extracellular (solid arrow) and intracellular within macrophages (open arrow), obtained via fine-needle aspiration of a cutaneous lesion (**2A**). Large cluster of extracellular *T. gondii* tachyzoites (arrow) obtained via fine-needle aspiration of a cutaneous lesion (**2B**) (Wright's stain, 1000 \times ; bar=10 μ m).

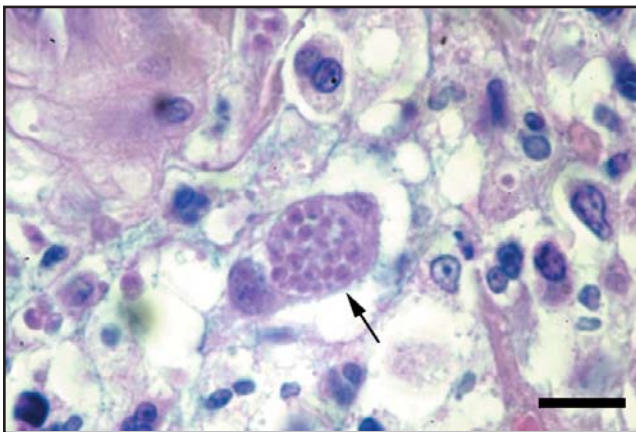


Figure 3—*Toxoplasma gondii* tachyzoites within a macrophage (arrow) in an area of pyogranulomatous dermatitis (Hematoxylin and eosin stain, 1000 \times ; bar=10 μ m).

The gross pulmonary nodules corresponded histologically to focal areas of necrosis. Fibrin, hemorrhage, and infiltration of large numbers of degenerative neutrophils and foamy macrophages with numerous intracellular tachyzoites were seen in the necrotic areas. Alveolar septa

surrounding the necrotic foci and throughout the lungs were variably thickened by fibrosis and mononuclear cell infiltration. Hyperplasia of the Type-2 pneumocytes was prominent in affected areas. Alveolar sacs were filled with foamy macrophages, and there were occasional tachyzoites within alveolar macrophages throughout the lungs. Areas of focal necrosis with tachyzoites were also observed in the heart and pancreas.

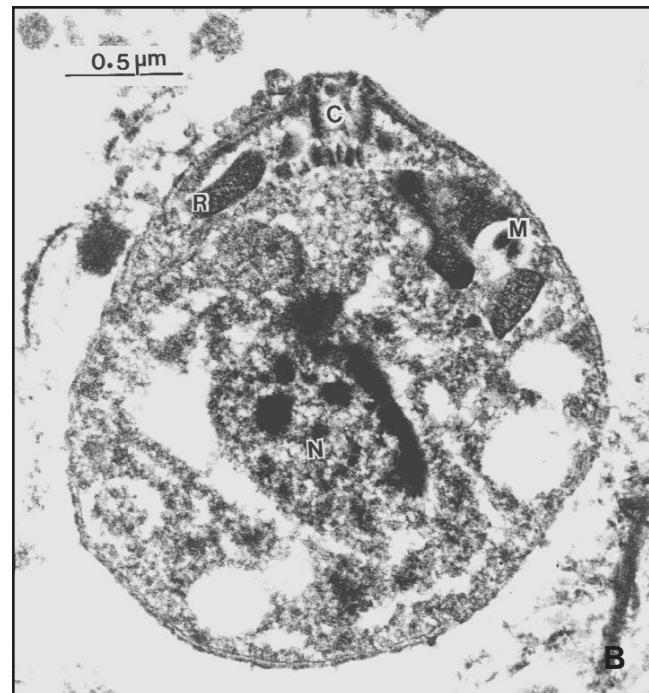
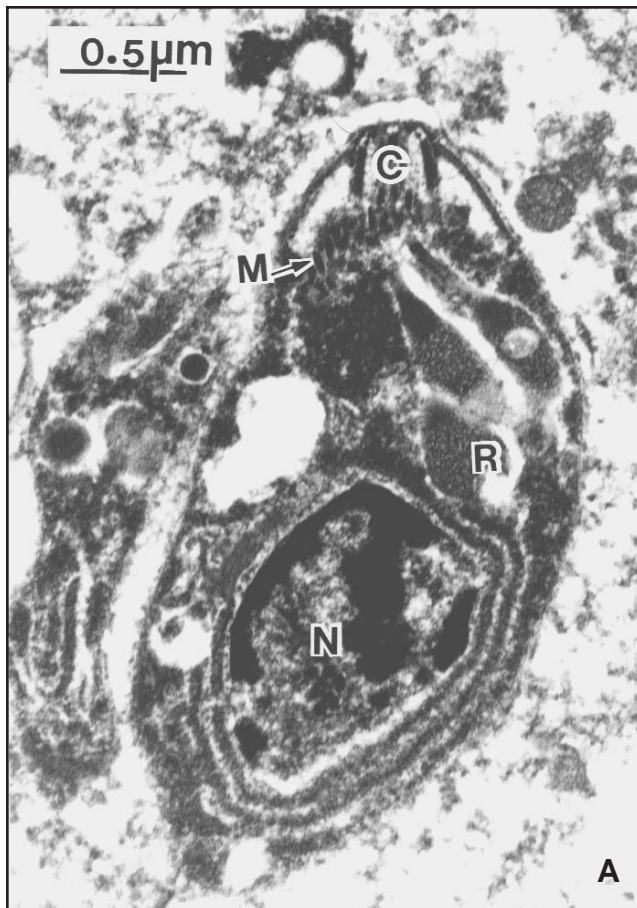
Random, multifocal, acute necrosis without visible tachyzoites was evident in the liver, in addition to lesions consistent with steroid hepatopathy. The IMHA appeared to be poorly controlled, as evidenced by prominent erythrophagocytosis in the splenic red pulp and lymph node medullary sinuses, and by bone marrow hypocellularity with a myeloid to erythroid ratio of 10:1. No histological abnormalities were detected in other organs, such as the kidneys, gastrointestinal tract, eyes, or brain.

Deparaffinized sections of skin were immunohistochemically stained with polyclonal antibodies to *T. gondii*, *N. caninum*, and *Sarcocystis neurona* (*S. neurona*) as described previously.^{16,17} Protozoa reacted positively with antibodies to *T. gondii*, but not with antibodies to *N. caninum* or *S. neurona*. In addition, sections were exposed to the bradyzoite-specifically expressed gene BAG-1 (previously called BAG-5) antibodies.¹⁸ A few organisms reacted positively with BAG-1 antibodies, indicating the presence of bradyzoites.

A deparaffinized section of skin was also processed for transmission electron microscopy to exclude the diagnosis of a *T. gondii*-like protozoa.⁵ Transmission electron microscopy showed tachyzoites dividing by endodyogeny; schizonts were not seen. Although the tissue was not well preserved, protozoa with the morphology of *T. gondii* tachyzoites were recognizable. Such morphology included a conoid, a few micronemes, and a few rhoptries with electron-lucent contents [Figures 4A, 4B].

Discussion

Cutaneous manifestations of protozoal disease in the dog are uncommon except in cases of cutaneous leishmaniasis.^{6,19,20} Organisms that are potential differential causes of cutaneous protozoosis include *Leishmania infantum*, *T. gondii*, *N. caninum*, *Caryospora* spp., and *Sarcocystis canis*.⁶ Cutaneous neosporosis is a rare disorder, having been reported in only six dogs.^{2,6,19} Cutaneous sarcocystosis has been reported in one rottweiler in the United States.⁶ To the authors' knowledge, cutaneous toxoplasmosis has not previously been described in the dog. Although dermatitis caused by a *T. gondii*-like organism in a dog has recently been described, electron microscopy excluded cutaneous toxoplasmosis.⁵ In a study of 100 cats with clinical toxoplasmosis, two cases of cutaneous toxoplasmosis were confirmed.¹⁰ In the dog reported here, the diagnosis of toxoplasmosis was based on parasite morphology and immunoreactivity in cutaneous lesions. The parasite divided into two by endodyogeny, thus excluding sarcocystosis. Organisms from cutaneous lesions did not react with *N. caninum* antibodies, and the dog was seronegative for *N. caninum* antibodies. Electron microscopy was consistent



Figures 4A, 4B—Transmission electron micrographs of two *T. gondii* tachyzoites from a cutaneous lesion. Note a conoid (C), a few rhoptries with electron-lucent contents (R), micronemes (M), and a nucleus (N).

with *T. gondii* and was incompatible with a recently described *T. gondii*-like organism.⁵

In humans, cases of acquired clinical toxoplasmosis almost always occur in immunosuppressed individuals and may produce a wide range of cutaneous manifestations.^{3,8,13,14,21,22} However, cutaneous manifestations of toxoplasmosis in people are rare.^{3,8,13,21} The histological findings of cutaneous and disseminated toxoplasmosis in the dog presented here were comparable to humans with acquired immunodeficiency syndrome.^{9,10,13,14,22}

Toxoplasmosis in both humans and animals is usually treated with clindamycin or a combination of a sulfonamide and pyrimethamine, with the aim of suppressing replication.^{2,3,14,23} Treatment does not often completely eradicate the organism, and permanent damage may occur to affected organs.^{2,4,9,14,23} In clinical reviews of toxoplasmosis in immunocompromised humans, most patients have shown marked clinical improvement or complete remission following treatment.^{9,17} Based on a generally favorable response to antibiotic therapy in immunosuppressed people, it is possible that treatment in the case presented here may have resulted in complete remission.^{7,14}

In the dog reported here, immunosuppression was probably induced by the administration of glucocorticoids, cyclosporine, and azathioprine. This dog may have had quiescent toxoplasmosis that subsequently became clinical, owing to immunosuppression. However, the dog may also

have been exposed to the organism after the initiation of immunosuppressive therapy. Although it was possible that *T. gondii* was contracted via one of the blood transfusions, this was unlikely. Of the five blood donors used, four were available for follow-up serology, and all were negative for *T. gondii* antibodies. Finally, it was possible that the initial episode of IMHA was triggered by latent toxoplasmosis. Serology for *T. gondii* was not available prior to the dog developing IMHA, so this possibility could not be assessed.

The clinical icterus and hepatic biochemical changes noted in the dog presented in this report were likely related to hemolysis and cholestasis. The hypocalcemia may have been related to the hypoalbuminemia; however, ionized calcium was not performed. Differential diagnoses for the erythroid hypoplasia were IMHA involving erythroid precursors and azathioprine-induced bone marrow suppression; however, the latter condition was considered unlikely as the white blood cell and platelet lines were normal.

Conclusion

This case demonstrated that toxoplasmosis may present with cutaneous manifestations in the dog. In addition, the organism was noted in the lungs, pancreas, and heart. The findings of cutaneous and disseminated toxoplasmosis in an immunosuppressed dog resembled reports of clinical toxoplasmosis in immunocompromised humans. To the

authors' knowledge, this is the first confirmed case of cutaneous toxoplasmosis reported in the dog.

^a Apo-prednisone; Apotex Inc., Toronto, Ontario, M9L 1T9, Canada

^b Gen-azathioprine; Genpharm Inc., Toronto, Ontario, M8Z 2S9, Canada

^c Neoral; Novartis Pharmaceuticals Canada Inc., Dorval, Quebec, H9S 1A9, Canada

^d Toxo-IHA test; Wampole Laboratories, Cranbury, NJ 08512

^e *Neospora caninum* antibody test kit; VMRD, Inc., Pullman, WA 99163

Acknowledgment

The authors thank John Jenkins, Armed Forces Institute of Pathology, Washington, D.C., for performing the electron microscopy.

References

- Dubey JP. *Toxoplasma*, *Neospora*, *Sarcocystis*, and other tissue cyst-forming coccidian of humans and animals. In: Kreier JP, ed. *Parasitic Protozoa*. 2nd ed. New York: Academic Press, 1993(6):1-158.
- Dubey JP, Lappin MR. Toxoplasmosis and neosporosis. In: Greene CE, ed. *Infectious Diseases of the Dog and Cat*. 2nd ed. Philadelphia: WB Saunders, 1998:493-509.
- Binazzi M. Profile of cutaneous toxoplasmosis. *Int J Dermatol* 1986;25:357-363.
- Urquhart GM, Armour J, Duncan JL, et al. *Veterinary Parasitology*. 2nd ed. Cambridge: Blackwell Science Inc., 1996:234-238.
- Dubey JP, Pimenta AL, Abboud LCS, et al. Dermatitis in a dog associated with an unidentified *Toxoplasma gondii*-like parasite. *Vet Parasitol* 2003;116:51-59.
- Ordeix L, Lloret A, Fondevila D, et al. Cutaneous neosporosis during treatment of pemphigus foliaceus in a dog. *J Am Anim Hosp Assoc* 2002;38:415-419.
- Ruskin J, Remington JS. Toxoplasmosis in the compromised host. *Ann Intern Med* 1976;84:193-199.
- Leyva WH, Cruz DJS. Cutaneous toxoplasmosis. *J Am Acad Dermatol* 1986;14:600-605.
- Smith JL. Long-term consequences of foodborne toxoplasmosis: effects on the unborn, the immunocompromised, the elderly, and the immunocompetent. *J Food Protect* 1997;60:1595-1611.
- Dubey JP, Carpenter JL. Histologically confirmed clinical toxoplasmosis in cats: 100 cases (1952-1990). *J Am Vet Med Assoc* 1993;203:1556-1566.
- Plumb DC. *Veterinary Drug Handbook*. 4th ed. White Bear Lake: PharmaVet Publishing, 2002:93-94,713-723.
- Dubey JP, Carpenter JL, Topper MJ, et al. Fatal toxoplasmosis in dogs. *J Am Anim Hosp Assoc* 1989;25:659-664.
- Arnold SJ, Kinney MC, McCormick MS, et al. Disseminated toxoplasmosis - unusual presentations in the immunocompromised host. *Arch Pathol Lab Med* 1997;121:869-873.
- Holliman RE. Toxoplasmosis and the acquired immune deficiency syndrome. *J Infect* 1988;16:121-128.
- Bernsteen L, Gregory CR, Aronson LR, et al. Acute toxoplasmosis following renal transplantation in three cats and a dog. *J Am Vet Med Assoc* 1999;215:1123-1126.
- Dubey JP, Garner MW, Willette MM, et al. Disseminated toxoplasmosis in magpie geese (*Anseranas semipalmata*) with large numbers of tissue cysts in livers. *J Parasitol* 2001;87:219-223.
- Dubey JP, Hamir AN. Immunohistochemical confirmation of *Sarcocystis neurona* infections in raccoons, cat, skunk, and pony. *J Parasitol* 2000;86:1150-1152.
- McAllister MM, Parmley SF, Weiss LM, et al. An immunohistochemical method for detecting bradyzoite antigen (BAG5) in *Toxoplasma gondii*-infected tissues cross-reacts with a *Neospora caninum* bradyzoite antigen. *J Parasitol* 1996;82:354-355.
- Scott DW, Miller WH, Griffin CE. *Muller & Kirk's Small Animal Dermatology*. 6th ed. Philadelphia: WB Saunders, 2001:531-538.
- Merchant SR, Taboada J. Systemic diseases with cutaneous manifestations. *Vet Clin North Am Small Anim Pract* 1995;25:945-959.
- Mawhorter SD, Effron D, Blinkhorn R, et al. Cutaneous manifestations of toxoplasmosis. *Clin Infect Dis* 1992;14:1084-1088.
- Tschirhart D, Klatt EC. Disseminated toxoplasmosis in the acquired immunodeficiency syndrome. *Arch Pathol Lab Med* 1988;112:1237-1241.
- Dubey JP, Metzger FL, Hattel AL, et al. Canine cutaneous neosporosis: clinical improvement with clindamycin. *Vet Dermatol* 1995;6:37-43.